

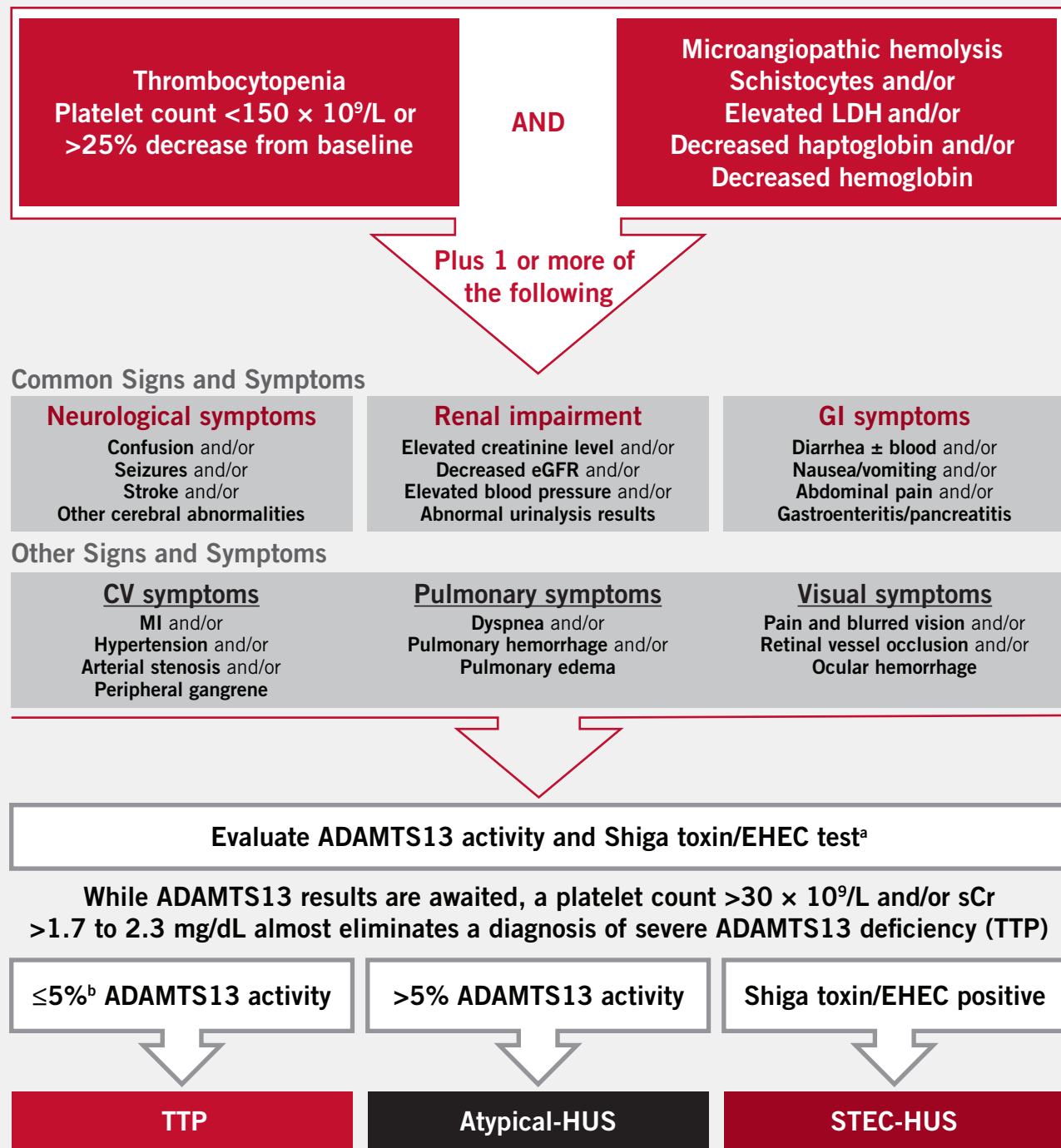
Identifying Atypical Hemolytic Uremic Syndrome in the Transplantation Setting

A Guide To Differential Diagnosis

Identifying Atypical-HUS in the Transplantation Setting

The information in this brochure is intended as educational information for healthcare professionals. It does not replace a healthcare professional's judgment or clinical diagnosis.

Differential Diagnosis of Atypical-HUS¹⁻⁴



TMA can also manifest in the presence of clinical conditions such as the following

- Pregnancy-postpartum
- Malignant/severe hypertension
- Solid organ transplantation
- Autoimmune disease (eg, SLE, scleroderma)
- Hematopoietic stem cell transplantation

^aShiga toxin/EHEC test is warranted with history/presence of GI symptoms. ^bRange found in published literature is $<5\%$ - 10% .

ADAMTS13, a disintegrin and metalloproteinase with a thrombospondin type 1 motif member 13; HUS, hemolytic uremic syndrome; CV, cardiovascular; eGFR, estimated glomerular filtration rate; EHEC, enterohemorrhagic *Escherichia coli*; GI, gastrointestinal; MI, myocardial infarction; sCr, serum creatinine; STEC-HUS, Shiga toxin-producing *Escherichia coli*-hemolytic uremic syndrome; SLE, systemic lupus erythematosus; TMA, thrombotic microangiopathy; TTP, thrombotic thrombocytopenic purpura.

Differential Diagnosis: Identifying Atypical-HUS in the Transplantation Setting

- Thrombotic microangiopathy (TMA) is a serious medical condition characterized by microangiopathic hemolytic anemia, thrombocytopenia, and end-organ injury³
- TMA has been associated with solid organ transplantation⁴ and is found in >40% of renal biopsy specimens during episodes of antibody-mediated rejection⁵
- Although antibody-mediated rejection is a common cause of TMA, many other factors can contribute to the development of posttransplantation TMA, including^{6,7}
 - Ischemia-reperfusion injury
 - Drug toxicity related to calcineurin inhibitors
 - Viral infections
 - Underlying atypical hemolytic uremic syndrome (atypical-HUS)
- Atypical-HUS is a disease caused by dysregulation of the alternative pathway of the complement system, leading to excessive complement activation and TMA^{4,8}
- Solid organ transplantation is a complement-amplifying condition that can cause manifestations of TMA in patients with atypical-HUS¹
 - The risk of TMA manifestations in patients with atypical-HUS following renal transplantation has been reported to range from 20% to more than 80%, depending on the presence of a specific genetic mutation⁹
 - Risk for TMA is also deemed high in patients without a genetic mutation who have received a renal transplant^{10,11}
- It is important to diagnose atypical-HUS promptly in patients who have received a renal transplant
 - In patients with atypical-HUS, posttransplantation TMA manifestations can significantly increase the risk for graft loss¹²
- Atypical-HUS should be considered if a patient presents with posttransplantation TMA and the following characteristics



- **Microangiopathic hemolysis**^{2,3,10,13,14}
 - Schistocytes or fragmented RBCs
 - Low haptoglobin level
 - Low hemoglobin level
 - Elevated lactate dehydrogenase level
 - Elevated bilirubin level

- **Thrombocytopenia**^{2,3,10,13,14}
- **Clinical involvement of ≥ 1 organ system (eg, kidney, GI tract, CNS)**^{2,3,10,13}
- **ADAMTS13 activity >5% and negative STEC test result**^{4,8,13,14}



- **Mutations or polymorphisms in genes such as *C3*, *CFB*, *CFH*, *CFHR1*, *CFI*, *MCP*, and *THBD***^{8,11,12,15}



- **Persistent TMA despite having addressed the potential cause (eg, management of antibody-mediated rejection, adjustment of immunosuppressant therapy, management of infection)**⁴



- **Family or individual history of TMA**^{10,16}
- **Neurological symptoms (eg, irritability, confusion, stroke)**^{9,13}

Case Study

Patient Overview¹⁷

- Female, aged 41 years, presented to emergency department with diarrhea, abdominal pain, and vomiting 13 days after renal transplantation
- Received a renal transplant from a deceased donor
 - Number of human leukocyte antigen incompatibilities was 1 for each locus (A, B, DR); cross-match was negative
 - Histology of allograft 1 day after transplantation was normal
- No family history of renal failure; developed ESRD following pregnancy complications

Clinical Presentation and Management¹⁷

Gestational hypertension following twin pregnancy; mild renal failure progressed to ESRD at age 36	Renal transplantation from deceased donor at age 41	Progress appeared normal	Diarrhea, abdominal pain, vomiting, anemia, hemolysis, renal impairment	Recurrent TMA (anemia, thrombocytopenia)
Before Transplantation	Renal Transplantation	7 Days Posttransplantation	13 Days Posttransplantation	6 Months After Starting Treatment for Rejection
Unspecific angiosclerotic lesions on renal biopsy Therapy: dialysis	Induction therapy: thymoglobulin, tacrolimus, mycophenolate, and methylprednisolone	Discharged from hospital	Diagnosis: antibody-mediated rejection Therapy: high-dose steroids, PE, monthly IVIg	No signs of antibody-mediated rejection on renal biopsy Diagnosis: atypical-HUS

ESRD, end-stage renal disease; HUS, hemolytic uremic syndrome; IVIg, intravenous immunoglobulin; PE, plasma exchange; TMA, thrombotic microangiopathy.

Laboratory Values¹⁷

- At presentation
 - An underlying dysregulation of the complement system was considered, but evaluations were negative
 - Low factor H activity was determined to be insufficient to consider a diagnosis of atypical-HUS at that time

Laboratory Test	Normal Values	7 Days Posttransplantation	At Presentation (13 Days posttransplantation)	6 Months After Starting Treatment for Antibody-Mediated Rejection
White blood cell count, $\times 10^3/\text{mm}^3$	4.2-11.4	4.2	7.2	2.6
Hematocrit, %	35.3-46.1	27.2	18.7	26
Hemoglobin, g/dL	12.0-16.0	9.0	6.4	8.6
Platelet count, $\times 10^9/\text{L}$	150-450	187	120	119
Haptoglobin, mg/dL	36-195	ND	<5	<5
Creatinine, mg/dL	0.6-1.3	1.2	3.3	1.9
Lactate dehydrogenase, U/L	100-190	185	685	700
Bilirubin, mg/dL	<1.2	0.2	1.5	1.1
Schistocytes per 1000 RBCs	0	ND	26	20
Differential diagnosis evaluations	No	Yes	Yes	Yes
Complement function tests				
CH50 activity	—	ND	Normal	Normal
Serum levels of C3, C4, FI, MCP (CD46)	—	ND	Normal	Normal
Factor H activity, %	86-103	ND	21	42
Anti-factor H antibodies	—	ND	None	None
C3d/C3	<1.4	ND	1.7	
ADAMTS13 activity, %	>5	ND	>5	>5
Stool test for Shiga toxin <i>Escherichia coli</i>	—	ND	Negative	Negative
Kidney allograft biopsy	—	—	TMA associated with antibody-mediated rejection	TMA (C4d staining negative), no signs of antibody-mediated rejection

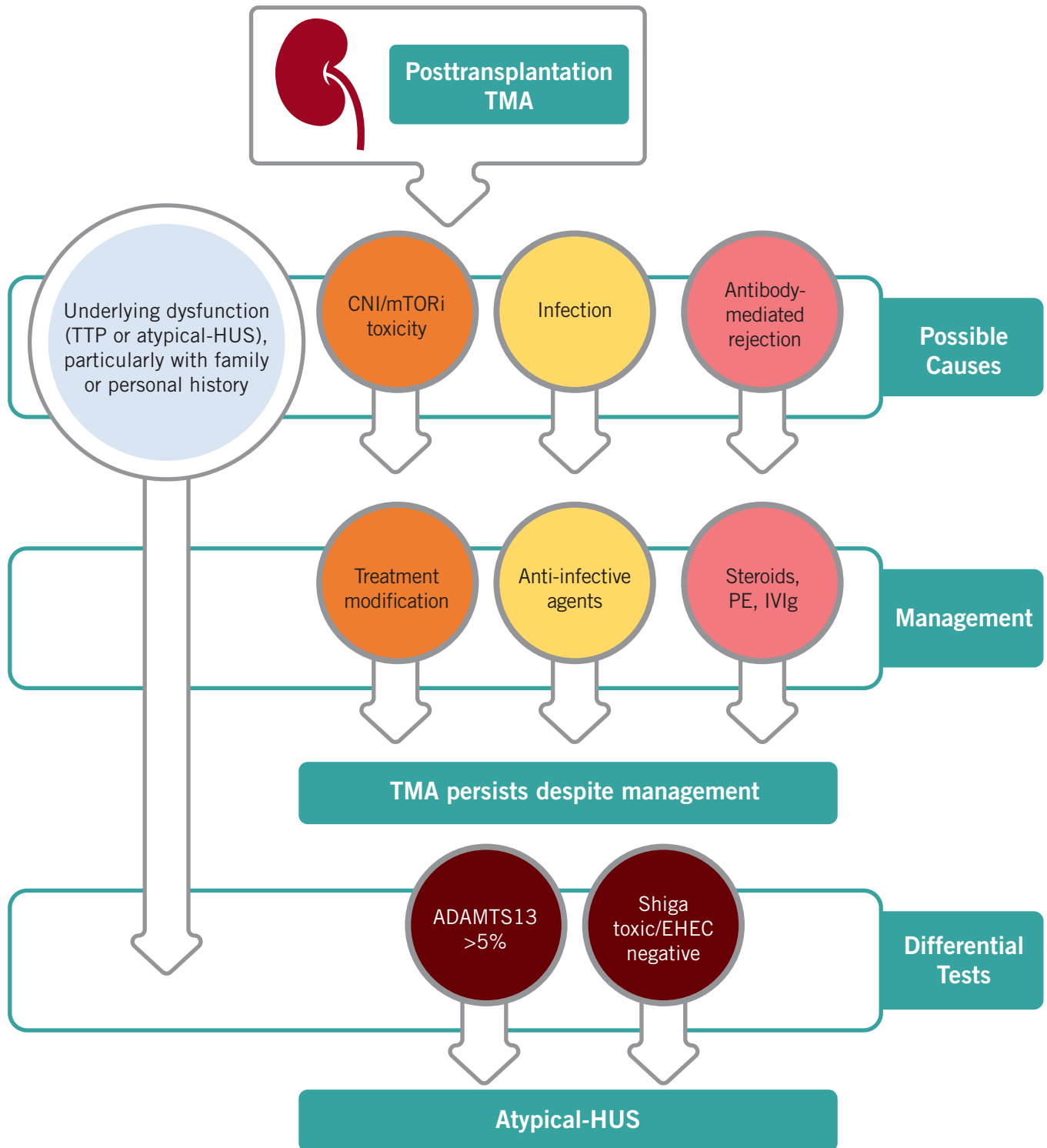
ADAMTS13, a disintegrin and metalloproteinase with a thrombospondin type 1 motif member 13; HUS, hemolytic uremic syndrome; ND, not determined; RBC, red blood cell; TMA, thrombotic microangiopathy.

Differential Diagnosis

- A diagnosis of atypical-HUS was made 6 months after the start of treatment for antibody-mediated rejection, based on
 - TMA recurrence in the absence of antibody-mediated rejection
 - Shiga toxin–negative stool test result
 - ADAMTS13 activity >5%, ruling out thrombotic thrombocytopenic purpura
- Genetic testing confirmed a heterozygous single nucleotide polymorphism in short consensus repeat 15 of complement factor H

Important Considerations for a Differential Diagnosis

Differentiation of atypical-HUS from other causes of posttransplantation TMA is essential for optimal management decisions^{4,6-8,12-14,18}



ADAMTS13, a disintegrin and metalloproteinase with a thrombospondin type 1 motif member 13; CNI, calcineurin inhibitor; ; EHEC, enterohemorrhagic *Escherichia coli*; HUS, hemolytic uremic syndrome; IVIg, intravenous immunoglobulin; mTORi, mammalian target of rapamycin inhibitor; PE, plasma exchange; STEC, Shiga toxin-producing *Escherichia coli*; TMA, thrombotic microangiopathy; TTP, thrombotic thrombocytopenic purpura.

Atypical-HUS is a serious disease caused by dysregulation of the alternative pathway of the complement system, leading to excessive complement activation and TMA^{4,8}

Solid organ transplantation is a complement-amplifying condition that can cause manifestations of TMA in patients with atypical-HUS^{2,4}

It is important to diagnose atypical-HUS promptly in patients who have received a transplant because posttransplantation TMA significantly increases the risk for graft loss¹²

If TMA is suspected, it is important to include a multidisciplinary team of specialists in the diagnostic process¹⁹

HUS, hemolytic uremic syndrome; TMA, thrombotic microangiopathy.

References

1. Laurence J, et al. *Clin Adv Hematol Oncol*. 2016;14:2-15.
2. Azoulay E, et al. *Chest*. 2017;152:424-434.
3. Goodship THJ, et al. *Kidney Int*. 2017;91:539-551.
4. Asif A, et al. *J Nephrol*. 2017;30:347-362.
5. Lefaucheur C, et al. *Am J Transplant*. 2007;7:832-841.
6. Chang A, et al. *Diagn Histopathol*. 2017;23:101-108.
7. Java A, et al. *Transpl Int*. 2015;28:1121-1125.
8. Jamme M, et al. *PLoS One*. 2017;12:e0177894.
9. Loirat C, et al. *Pediatr Transpl*. 2008;12: 619-629.
10. Campistol JM, et al. *Nefrologia*. 2015;35:421-447.
11. Zuber J, et al. *Transplant Rev*. 2013;27:117-125.
12. Le Quintrec M, et al. *Am J Transpl*. 2013;13:663-675.
13. Biswas A, et al. *Chest*. 2017;151:e63-e68.
14. Vardas PN, et al. *J Card Surg*. 2015;30:373-375.
15. Noris M, Remuzzi G. *Nat Rev Nephrol*. 2014;10:174-180.
16. Zuber J, et al. *Nat Rev Nephrol*. 2012;8:643-657.
17. Broeders EN, et al. *BMJ Case Rep*. 2014;doi:10.1136/bcr-2014-207630.
18. Loupy A, et al. *Am J Transplant*. 2017;17:28-41.
19. Rivera MGU, et al. *PLoS One*. 2018;13:e0206558.