

Atypical Hemolytic Uremic Syndrome (atypical-HUS): Identification and Management Considerations

This promotional program is sponsored by Alexion Pharmaceuticals, Inc.
© 2021, Alexion Pharmaceuticals, Inc. All rights reserved.
US/UNB-a/0113

Instructions for use

When using this presentation, please keep in mind the following instructions for use:

- These slides should not be modified in any way from their original version.
- This presentation is intended to be reviewed for individual use by healthcare professionals for educational purposes. It is not to be presented.
- The material contained within is not appropriate for use in continuing medical education (CME) content or programs.

US/UNB-a/0113 2

The objectives of this presentation are as follows

- Describe the clinical considerations in identifying atypical-HUS related thrombotic microangiopathy (TMA) and review the etiologies associated with it
- Increase confidence in diagnosing atypical-HUS associated with a complement-amplifying condition and recognize the importance of the ADAMTS13 assay and the timing of that assay
- Recognize the limitations of plasma therapy in atypical-HUS and understand factors that inform appropriate long-term management of patients with atypical-HUS

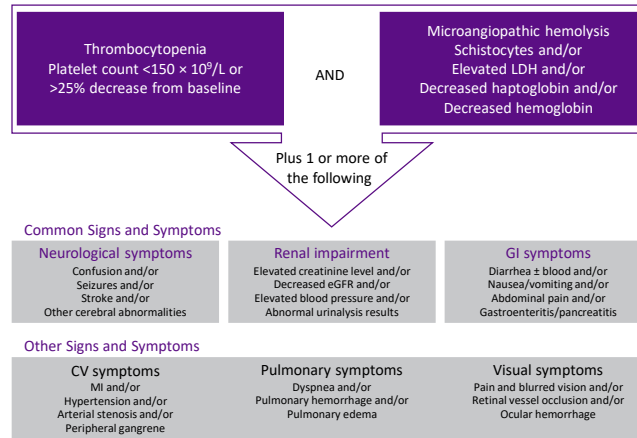
Following a review of this slide deck, we will give you the choice of 6 different patient cases to see how this information can be applied in different clinical scenarios

Defining TMA and its etiologies

US/UNB-a/0113

What is thrombotic microangiopathy (TMA)?

Clinical signs indicating a TMA¹⁻³

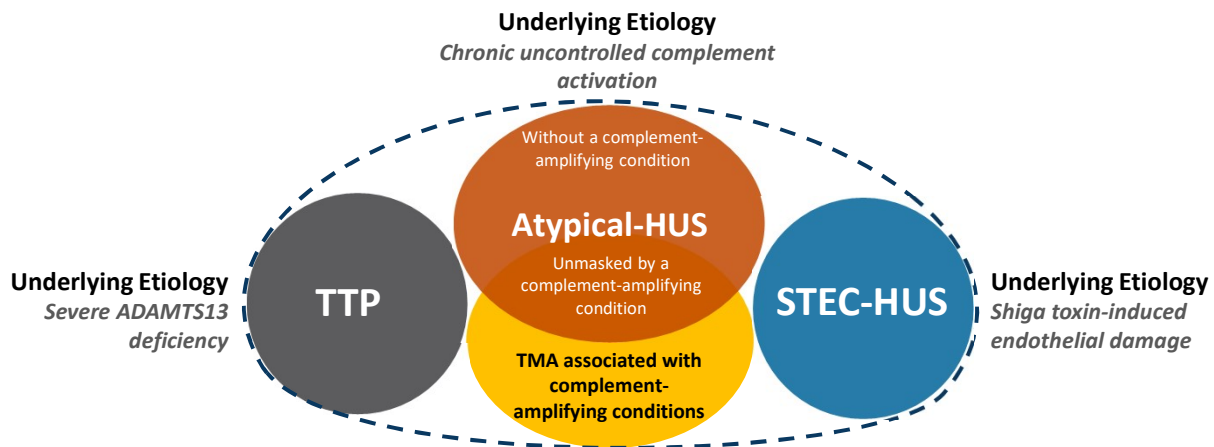


CV=cardiovascular; eGFR=estimated glomerular filtration rate; GI=gastrointestinal; LDH=lactate dehydrogenase; MI=myocardial infarction.

1. Goodship THJ, et al. *Kidney Int.* 2017;91(3):539-551. 2. Laurence J, et al. *Clin Adv Hematol Oncol.* 2016;14(11):2-15. 3. Azoulay E, et al. *Chest.* 2017;152(2):424-434.

US/UNB-a/0113 4

The underlying etiologies of TMAs may include TTP, atypical-HUS, or STEC-HUS¹



*Diagram is for illustrative purposes only.

ADAMTS13=a disintegrin and metalloproteinase with a thrombospondin type 1 motif member 13; STEC-HUS=Shiga toxin-producing *Escherichia coli* hemolytic uremic syndrome; TMA=thrombotic microangiopathy; TTP=thrombotic thrombocytopenic purpura.

1. Azoulay E, et al. *Chest*. 2017;152(2):424-434.

US/UNB-a/0113 5

At this point, it's reasonable to ask, "what are the underlying causes of TMAs?" As it turns out, there are several underlying etiologies, as represented by this Venn diagram. They include: thrombotic thrombocytopenic purpura (TTP), Shiga toxin-producing *Escherichia coli* (STEC), and atypical-HUS. You can see that they are all unified by chronic uncontrolled complement activation; sometimes this is due to a complement-amplifying condition. The next slide will review these potential complement-amplifying conditions in detail.

TMA^s can be associated with various complement-amplifying conditions^{1,2}

Examples of complement-amplifying conditions



Pregnancy^a/
postpartum



Malignant
hypertension



Transplantation
(ie, solid organ transplant,
bone marrow transplant)



Autoimmune diseases
(eg, systemic lupus
erythematosus)



Medications
(eg, immunosuppressants,
chemotherapy)



Infections



Glomerulonephritis



Malignancy



Surgery or trauma

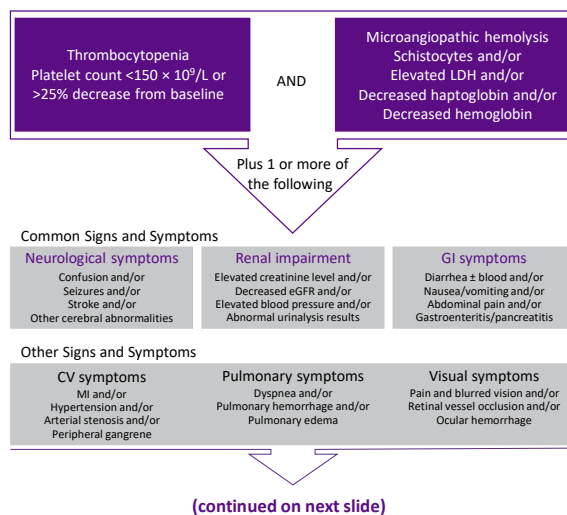
^aPregnancy-associated conditions such as HELLP (hemolysis, elevated liver enzymes, low platelet counts) syndrome.

1. Campistol JM, et al. *Nefrologia*. 2015;35(5):421-447. 2. Laurence J, et al. *Clin Adv Hematol*. 2016;14(11):2-15.

Atypical-HUS: identification and impact on the patient

US/UNB-a/0113

Identifying the etiology of a TMA requires a differential diagnosis¹⁻³



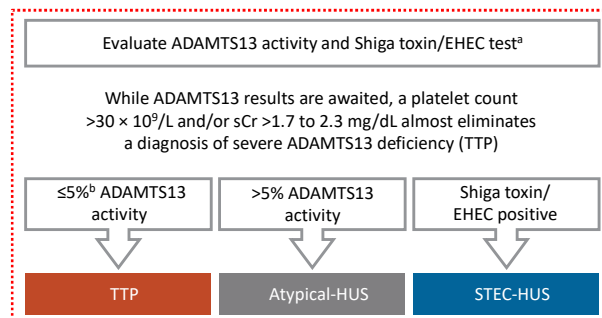
CV=cardiovascular; eGFR=estimated glomerular filtration rate; GI=gastrointestinal; LDH=lactate dehydrogenase; MI=myocardial infarction; TMA=thrombotic microangiopathy.

1. Goodship THJ, et al. *Kidney Int.* 2017;91(3):539-551. 2. Laurence J, et al. *Clin Adv Hematol Oncol.* 2016;14(11):2-15. 3. Azoulay E, et al. *Chest.* 2017;152(2):424-434.

US/UNB-a/0113 8

A diagnosis of TMA is based on the presence of thrombocytopenia and microangiopathic hemolysis plus 1 or more of the following: neurological symptoms, renal impairment, gastrointestinal symptoms, cardiovascular symptoms, pulmonary symptoms, or visual symptoms. Specific signs or symptoms associated with each of these are listed on the slide.

Identifying the etiology of a TMA requires a differential diagnosis (cont)¹⁻⁴



TMA can also manifest in the presence of clinical conditions such as the following:

- Pregnancy/postpartum
- Malignant/severe hypertension
- Solid organ transplantation
- Autoimmune disease (eg, SLE, scleroderma)
- Hematopoietic stem cell transplantation

ADAMTS13=a disintegrin and metalloproteinase with a thrombospondin type 1 motif member 13; EHEC=enterohemorrhagic *Escherichia coli*; sCr=serum creatinine; SLE=systemic lupus erythematosus; STEC-HUS=Shiga toxin-producing *Escherichia coli* hemolytic uremic syndrome; TMA=thrombotic microangiopathy; TTP=thrombotic thrombocytopenic purpura.

^aShiga toxin/EHEC test is warranted with history/presence of GI symptoms. ^bRange found in published data is 5% to 10%.

1. Laurence J, et al. *Clin Adv Hematol Oncol*. 2016;14(11):2-15. 2. Azoulay E, et al. *Chest*. 2017;152(2):424-434. 3. Goodship THJ, et al. *Kidney Int*. 2017;91(3):539-551. 4. Asif A, et al. *J Nephrol*. 2017;30(3):347-362.

US/UNB-a/0113 9

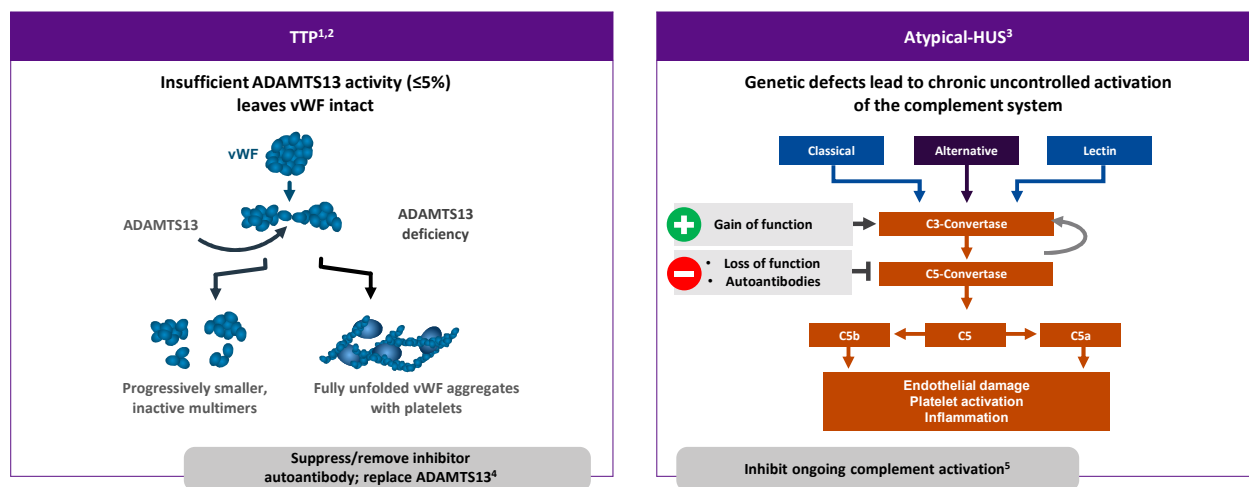
A diagnosis of TMA is based on the presence of thrombocytopenia and microangiopathic hemolysis plus 1 or more of the following: neurological symptoms, renal impairment, gastrointestinal symptoms, cardiovascular symptoms, pulmonary symptoms, or visual symptoms. Specific signs or symptoms associated with each of these are listed on the slide.

Where TTP and STEC-HUS have been ruled out, the TMA can be attributed to complement dysregulation. Atypical-HUS is a complement mediated TMA (CM-TMA) that has been more broadly or narrowly defined in different contexts, based on such factors as the presence and nature of a trigger and/or identification of an underlying genetic mutation.

References

1. Laurence J, et al. *Clin Adv Hematol Oncol*. 2016;14(11):2-15.
2. Jokiranta TS. *Blood*. 2017;129:2847-2856.
3. Hofer J, et al. *Front Pediatr*. 2014;2:1-16.

TTP and atypical-HUS are driven by different pathophysiologic processes and require different management strategies



ADAMTS13=a disintegrin and metalloproteinase with a thrombospondin type 1 motif member 13; HUS=hemolytic uremic syndrome; TTP=thrombotic thrombocytopenic purpura; vWF= von Willebrand factor.

1. Tsai HM. *Int J Hematol*. 2010;91(1):1-19. 2. Sadler JE. *Blood*. 2008;112(1):11-18. 3. Noris M, et al. *Nat Rev Nephrol*. 2012;8(11):622-633. 4. Tsai HM. *Am J Med*. 2013;126(3):200-209. 5. Laurence J. *Clin Adv Hematol Oncol*. 2012;10(suppl 17):1-12.

US/UNB-a/0113 10

TTP results from insufficient ADAMTS13 activity of less than 5%, either caused by a mutation to the ADAMTS13 gene or autoantibodies to ADAMTS13¹

- ADAMTS13 cleaves von Willebrand factor, controlling clot size by preventing excessive platelet binding¹
- Without ADAMTS13, von Willebrand factor multimerizes and exposes many platelet-binding sites, leading to excessive platelet binding and uncontrollable clot formation¹
- The primary management goals for TTP are suppression and/or removal of inhibitory autoantibodies or replenishing ADAMTS13 levels in the blood²

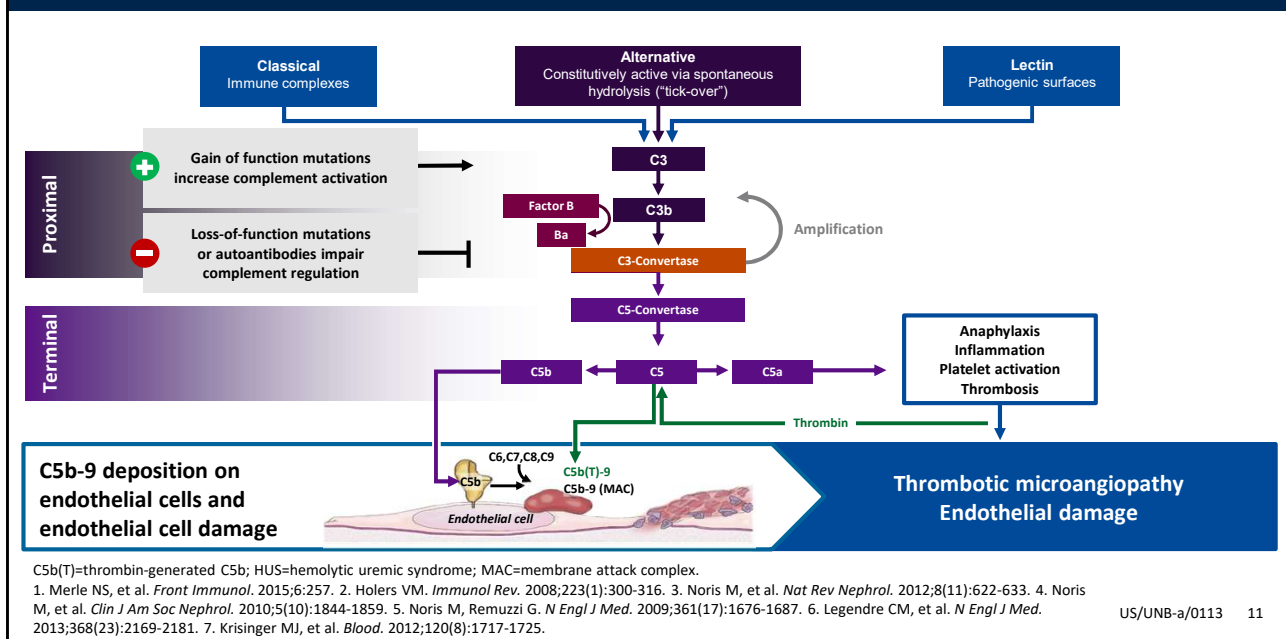
Atypical-HUS results from genetic defects of complement proteins, leading to uncontrolled complement activation³

- The alternative pathway of the complement system is upregulated by either gain-of-function mutations in activators, loss-of function mutations in inhibitors, or autoantibodies to inhibitors⁴
- This leads to endothelial damage, platelet activation, and inflammation⁴

References

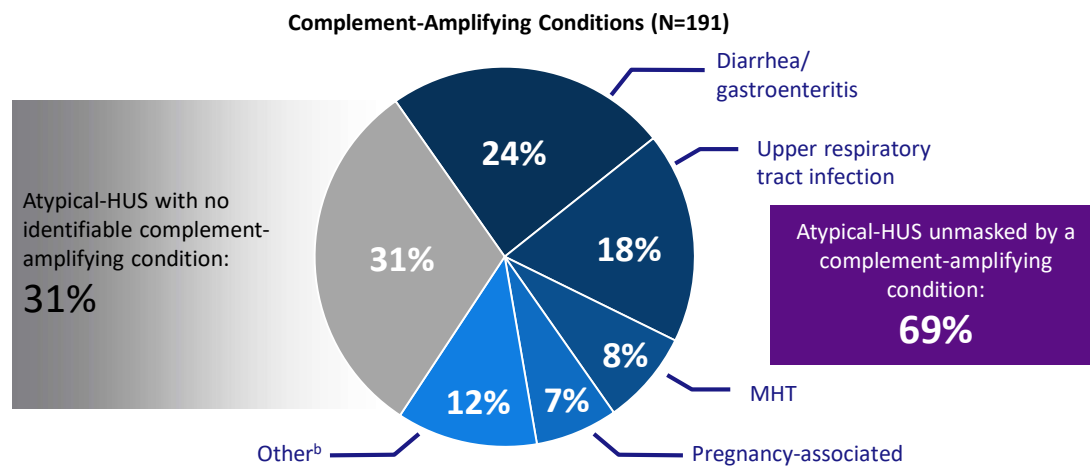
1. Tsai HM. *Int J Hematol*. 2010;91(1):1-19.
2. Tsai HM. *Am J Med*. 2013;126(3):200-209.
3. Laurence J. *Clin Adv Hematol Oncol*. 2012;10(suppl 17):1-12.
4. Noris M, et al. *Nat Rev Nephrol*. 2012;8(11):622-633.

Complement dysregulation leads to atypical-HUS¹⁻⁷



As noted on the last slide, the alternative pathway of the complement system is upregulated by either gain-of-function mutations in activators, loss-of function mutations in inhibitors, or autoantibodies to inhibitors. The culmination of these defects leads to endothelial damage. In addition, however, anaphylaxis, inflammation, platelet activation, and thrombosis can also occur.

The majority of atypical-HUS cases are unmasked by complement-amplifying conditions, but for 1/3 of patients that complement-amplifying condition is unidentifiable^a



HUS=hemolytic uremic syndrome; MHT=malignant hypertension.

^aAnalysis is based on the screening of 273 consecutive patients with atypical-HUS for complement abnormalities registered in the International Registry of Recurrent and Familial HUS/TTP from 1996-2007.

^bTransplant associated (5%); glomerulopathy (4%); systemic disease, such as SLE or scleroderma (2%); malignancy (1%).

Noris M, et al. *Clin J Am Soc Nephrol.* 2010;5(10):1844-1859.

US/UNB-a/0113 12

Next, let's discuss the likelihood of atypical-HUS presenting with complement-amplifying conditions. An analysis based on the screening of 273 consecutive patients with atypical-HUS for complement abnormalities registered in the International Registry of Recurrent and Familial HUS/TTP from 1996-2007 showed that atypical-HUS is unmasked by a complement-amplifying condition in 69% of patients. Among patients in whom atypical-HUS was unmasked by a complement-amplifying condition, 24% had diarrhea or gastroenteritis, 18% had upper respiratory tract infection, 8% had malignant hypertension, and 7% had pregnancy-associated complications.

Patients with atypical-HUS are at ongoing risk of systemic, life-threatening, and sudden complications¹⁻⁴

Atypical-HUS patients can show involvement in more than one organ system^{5-9,a}

Central nervous system: Up to 25% of patients experience neurological symptoms⁶

- Confusion⁷
- Encephalopathy^{5,8}
- Stroke⁵
- Seizures⁷

GI: Up to 47% of patients experience GI symptoms⁶

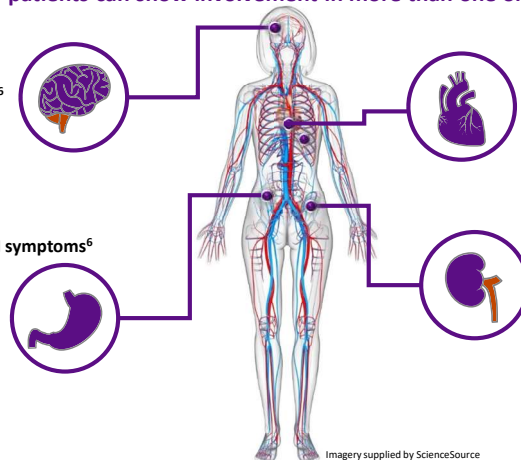
- Colitis⁵
- Abdominal pain⁷
- Pancreatitis⁵
- Nausea/vomiting⁵
- Gastroenteritis³
- Diarrhea⁷

CV: Up to 33% of patients experience CV symptoms⁶

- Arterial thrombosis⁵
- Vascular stenosis⁸
- Hypertension⁷
- Cardiomyopathy⁷
- Myocardial infarction^{5,8}

Renal: 49% progress to ESRD 5 years after diagnosis⁶

- Elevated creatinine⁷
- Decreased eGFR¹
- Proteinuria⁹



Imagery supplied by ScienceSource

CV=cardiovascular; eGFR=estimated glomerular filtration rate; ESRD=end-stage renal disease; GI=gastrointestinal; HUS=hemolytic uremic syndrome.

^aThe organ-specific symptoms associated with atypical-HUS are reported from the published literature and are not limited to only those listed in this slide.

1. Legendre CM, et al. *N Engl J Med*. 2013;368(23):2169-2181. 2. Azoulay E, et al. *Chest*. 2017;152(2):424-434. 3. Goodship THJ, et al. *Kidney Int*. 2017;91(3):539-551.

4. Fremeaux-Bacchi V, et al. *Clin J Am Soc Nephrol*. 2013;8(4):554-562. 5. Campistol JM, et al. *Nefrologia*. 2015;35(5):421-447. 6. Schaefer F, et al. *Kidney Int*. 2018;94(2):408-418.

7. Jamme M, et al. *PLoS One*. 2017;12(5):e0177894. 8. Hofer J, et al. *Front Pediatr*. 2014;2:1-16. 9. Krishnappa V, et al. *Ther Apher Dial*. 2018;22(2):178-188.

US/UNB-a/0113 13

Atypical-HUS can cause symptoms, and sometimes damage, to a variety of different organ systems, including the central nervous system, cardiovascular system, and the gastrointestinal system. In fact, CV complications can occur at presentation or following hematological normalization and are potentially fatal^{1,2}

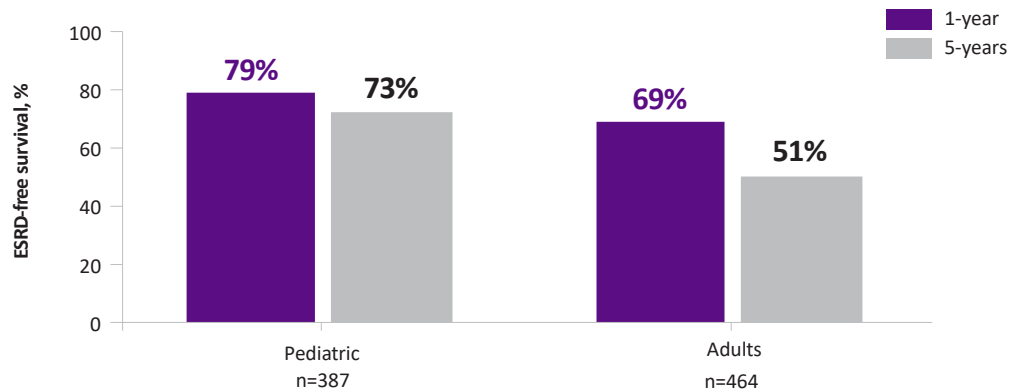
References

1. Noris M, Remuzzi G. *Nat Rev Nephrol*. 2014;10(3):174-180.
2. Roumenina LT, et al. *Blood*. 2012;119:4182-4191.

The risk of TMA is ongoing, unpredictable, and life-threatening in patients with atypical-HUS¹⁻⁴

- It is imperative that patients be diagnosed and managed appropriately as early as possible⁵

Pediatric patients have a lower risk of developing ESRD compared with adult patients (adjusted hazard ratio 0.55 [95% CI, 0.41-0.73])^{3,a}



CI=confidence interval; ESRD=end-stage renal disease; HUS=hemolytic uremic syndrome; TMA=thrombotic microangiopathy.

^aGlobal, observational study of atypical-HUS, including both retrospective and prospective enrollment. At time of data cutoff (November 30, 2015), 851 patients were enrolled.

1. Legendre CM, et al. *N Engl J Med*. 2013;368(23):2169-2181. 2. Noris M, et al. *Clin J Am Soc Nephrol*. 2010;5(10):1844-1859. 3. Schaefer F, et al. *Kidney Int*. 2018;94(2):408-418. 4. Fremeaux-Bacchi V, et al. *Clin J Am Soc Nephrol*. 2013;8(4):554-562. 5. Goodship THJ, et al. *Kidney Int*. 2017;91(3):539-551.

US/UNB-a/0113 14

It is imperative that patients be diagnosed and managed appropriately as early as possible. These data here emphasize this point. As we can see with this observational study, pediatric patients have a lower risk of developing end-stage renal disease compared with adult patients (adjusted hazard ratio 0.55 [95% CI, 0.41-0.73]); sex, race, family history of atypical-HUS, time from initial presentation to diagnosis, and potential complement-activating conditions were not associated with ESRD risk.¹

Reference

- Schaefer F, et al. *Kidney Int*. 2018;94(2):408-418.

Family history and/or medical history can increase the suspicion of atypical-HUS



Family History


Relatives who have experienced signs/symptoms consistent with TMA¹

Examples: Unexplained renal failure or CV disease due to unknown causes²

Medical History

Previous signs/symptoms consistent with TMA³

Examples: Hypertension, unexplained stroke/MI, preeclampsia/HELLP syndrome persisting after pregnancy^{2,4,5}



CV=cardiovascular; HELLP=hemolysis, elevated liver function, and low platelet counts; HUS=hemolytic uremic syndrome; MI=myocardial infarction; TMA=thrombotic microangiopathy.

1. Fremeaux-Bacchi V, et al. *Clin J Am Soc Nephrol*. 2013;8(4):554-562. 2. Lhotta K, et al. *Clin J Am Soc Nephrol*. 2009;4(8):1356-1362. 3. Barbour T, et al. *Nephrol Dial Transplant*. 2012;27(7):2673-2685. 4. Tsai HM. *Transfus Med Rev*. 2014;28(4):187-197. 5. Hofer J, et al. *Front Pediatr*. 2014;2:97.

US/UNB-a/0113 15

While waiting for ADAMTS13 activity results, any information that may substantiate the suspicion of atypical-HUS would be helpful in the diagnosis.

Family history and medical history may help substantiate the suspicion of atypical-HUS. If a physician suspects atypical-HUS, it may be informative to ask the patient if (s)he has relatives that have experienced signs or symptoms consistent with TMAs, such as unexplained renal failure or cardiovascular disease due to unknown causes. Also, any previous signs or symptoms consistent with TMA, such as hypertension, unexplained stroke, myocardial infarction, preeclampsia, or hemolysis, elevated liver enzymes, low platelet counts (HELLP) syndrome persisting after pregnancy may substantiate the suspicion of atypical-HUS.

Next, we consider other findings that may also substantiate the suspicion of atypical-HUS.

Complement results or renal biopsy, if available, can also help substantiate the suspicion of atypical-HUS


Complement Levels

Low C3/normal C4 levels suggest alternative pathway activation, but up to 80% of patients with atypical-HUS have normal serum C3 levels¹



Biopsy

If obtained for other reasons, renal biopsy may be useful to confirm TMA lesions in some patients^{1,2}



HUS=hemolytic uremic syndrome; TMA=thrombotic microangiopathy.

1. Laurence J. *Clin Adv Hematol Oncol*. 2012;10(suppl 17):1-12. 2. Campistol JM, et al. *Nefrologia*. 2015;35(5):421-447.

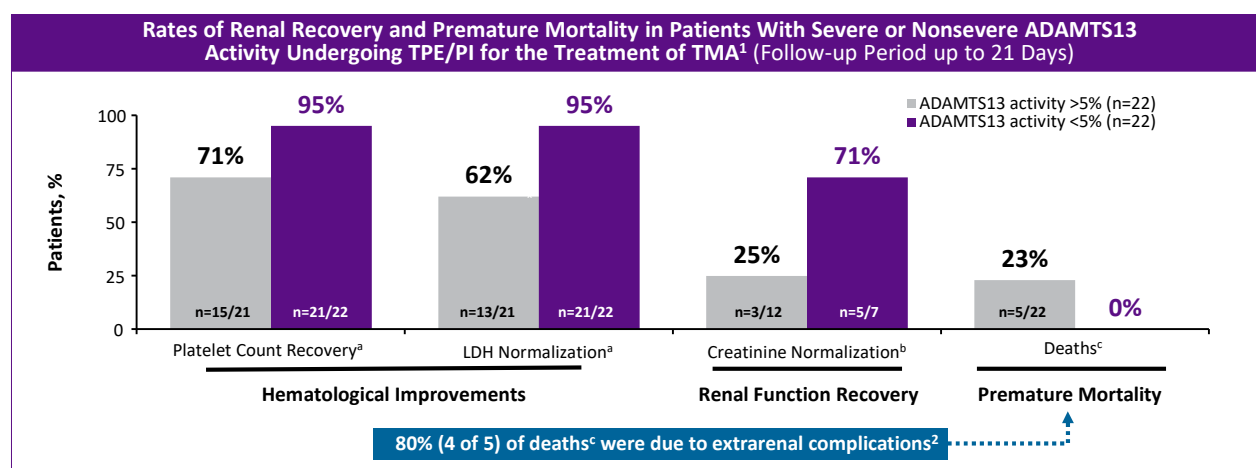
US/UNB-a/0113 16

We have previously reviewed that atypical-HUS is a disease of complement dysregulation involving the alternative pathway. A low C3/normal C4 level suggests alternative pathway activation. So, measuring C3 and C4 levels may substantiate the atypical-HUS diagnosis in some patients. However, 80% of patients with atypical-HUS have normal serum C3 levels. Therefore, C3 may be too inconsistent for diagnostic purposes.

Atypical-HUS: management considerations

US/UNB-a/0113

In patients with and without severe ADAMTS13 deficiency who receive PE, mortality outcomes differ



ADAMTS13=a disintegrin and metalloproteinase with a thrombospondin type 1 motif member 13; LDH=lactate dehydrogenase; MI=myocardial infarction; PI=plasma infusion; TMA=thrombotic microangiopathy; TPE=therapeutic plasma exchange.

^aOf patients with available data. ^bOf patients with abnormal creatinine level at baseline. ^cNon-ST-segment elevation MI/aspiration pneumonia, non-ST-segment elevation MI/abdominal abscess, multiorgan failure, respiratory failure, sepsis.²

1. Pishko AM, Arepally GM. *Blood*. 2014;124:4192. 2. Pishko AM, Arepally GM. Presented at: 56th American Society of Hematology Annual Meeting and Exposition; December 6-9, 2014; San Francisco, CA. Poster 4192.

US/UNB-a/0113 18

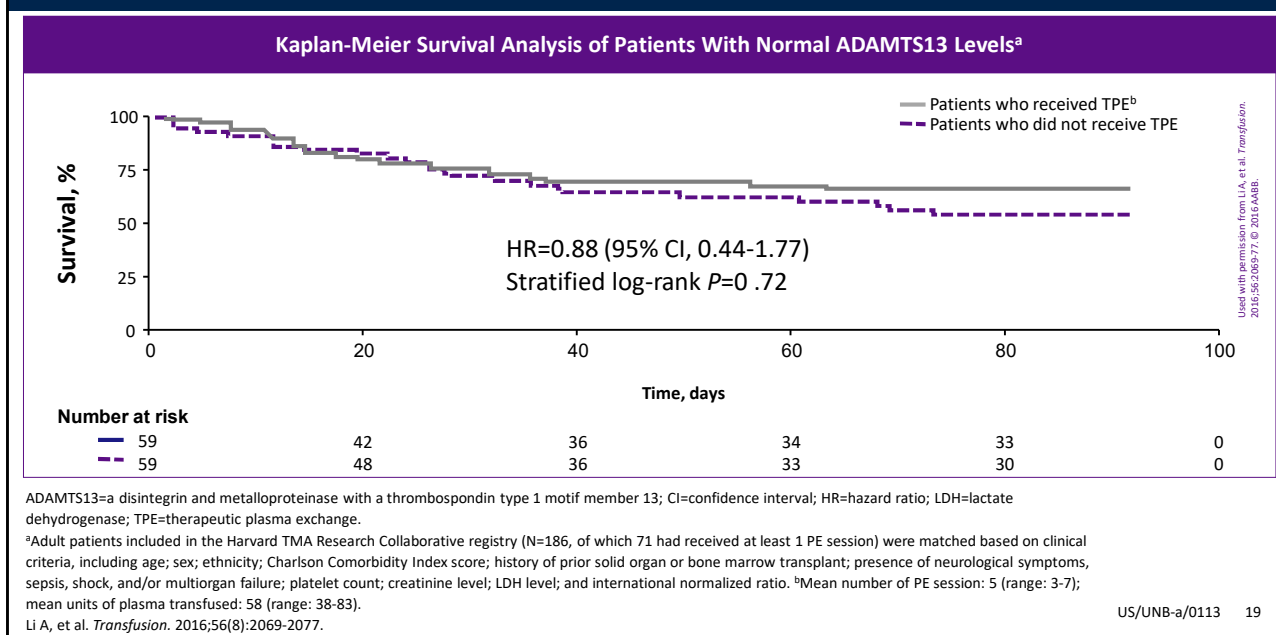
Next, we will review the effect of therapeutic plasma exchange on patients with an ADAMTS13 activity of >5% or <5%.

- In this study by Pishko et al, patients had either severe ADAMTS13 deficiency (less than 5%) or non-severe ADAMTS13 deficiency (greater than 5%).¹
- Daily hematological laboratory values and time to hematological recovery were collected and compared between the two groups.¹
- More deaths were observed in patients without severe ADAMTS13 deficiency¹
- Hematological recovery was observed in both groups, but plasma exchange did not prevent premature mortality and resulted in limited renal recovery in patients without severe ADAMTS13 deficiency.¹
- Therefore, patients with an ADAMTS13 activity of >5% or <5% are treated with PE and have hematological remission that may appear normal based on laboratory values but are still at risk of organ damage and death.²

References

1. Pishko AM, Arepally GM. *Blood*. 2014;124:4192.
2. Laurence J, et al. *Clin Adv Hematol Oncol*. 2016;14(11):2-15.

Patients without severe ADAMTS13 deficiency do not have a significant clinical benefit from TPE



Let's now review data on the survival of patients without severe ADAMTS13 deficiency who are treated with therapeutic plasma exchange.

- All patients in this study had ADAMTS13 levels greater than 10% and TMA
- Outcomes were compared between patients who did and did not receive plasma exchange therapy
 - Patients were matched based on clinical criteria including age; sex; ethnicity; Charlson Comorbidity Index score; history of prior solid organ or bone marrow transplant; presence of neurological symptoms, sepsis, shock, and/or multiorgan failure; platelet count; creatinine level; LDH level; and international normalized ratio
- Patients who received plasma exchange therapy did not have improved rates of survival, suggesting that there were no additional clinical benefits with plasma exchange in patients with ADAMTS13 levels greater than 10%
- Clinically relevant variables such as serum creatinine, alanine aminotransferase, the platelet count on Day 4, the presence of sepsis, shock or multiorgan failure at presentation, and Charlson comorbidity index independently predicted 90-day mortality

This data shows that PE is not an adequate management strategy for patients with ADAMTS13 levels greater than 10%. Also based on these data, we can see that timely diagnosis is crucial to allow patients to receive appropriate management.

Reference

1. Li A, et al. *Transfusion*. 2016;56:2069-2077.

Potential exposure to any complement-amplifying condition may lead to TMA manifestations in patients with atypical-HUS¹⁻⁴

Examples of factors that may increase risk for TMA manifestations in patients with atypical-HUS include^{5,6,a}



HISTORY OF RENAL TRANSPLANT^{3,7}

- The risk of atypical-HUS recurrence following transplantation has been reported to range from 20% to 88%, depending on the presence of a specific genetic mutation⁸
- Risk for TMA is also deemed high in patients without a genetic mutation who have received a renal transplant^{4,6}
- Risk for allograft loss is high in patients with atypical-HUS^{3,9,10}



AGE OF PATIENT¹¹

- Children are considered to be at high risk for recurrent TMA due to the frequency of common events that lead to complement activation in this age group¹¹



IDENTIFIED GENETIC MUTATION^{3,12,13}

- Clinical studies show that mutations in complement genes are associated with higher risk of TMA^{3,12,13}



PREGNANCY/POSTPARTUM^{4,14-16}

- Patients with atypical-HUS are at risk for TMA manifestations during the pregnancy/postpartum period¹⁴⁻¹⁶ due to factors such as infection, hemorrhage, and HELLP syndrome^{4,14}



CLINICAL HISTORY OR FAMILY HISTORY OF TMA^{3,6,12,17}

- Past TMA manifestations suggest high risk for subsequent TMA in the presence of complement-amplifying conditions^{6,12}
- Patients with family history of disease have a higher rate of disease progression; rate of end-stage renal disease or death has been reported to be between 50% and 80%^{3,6}

HELLP=hemolysis, elevated liver enzymes, low platelet counts; HUS=hemolytic uremic syndrome; TMA=thrombotic microangiopathy.

^aThis is not a comprehensive list but is intended to provide examples of factors that may increase risk for TMA. Anything that amplifies complement is a risk factor for TMA.¹⁻⁴

1. Schaefer F, et al. *Kidney Int.* 2018;94(2):408-418. 2. Goodship THJ, et al. *Kidney Int.* 2017;91(3):539-551. 3. Noris M, et al. *Clin J Am Soc Nephrol.* 2010;5(10):1844-1859. 4. Asif A, et al. *J Nephrol.* 2017;30(3):347-362. 5. Campistol JM, et al. *Nefrologia.* 2015;35(5):421-447. 6. Macia M, et al. *Clin Kidney J.* 2017;10(3):310-319. 7. Zuber J, et al. *Transplant Rev.* 2013;27(4):117-125. 8. Loirat C, Fremeaux-Bacchi V. *Pediatr Transplant.* 2008;12(6):619-629. 9. Bresin E, et al. *Clin J Am Soc Nephrol.* 2006;1(1):88-99. 10. Caprioli J, et al. *Blood.* 2006;108(4):1267-1279. 11. Loirat C, et al. *Pediatr Nephrol.* 2016;31(1):15-39. 12. Fakhouri F, et al. *Clin J Am Soc Nephrol.* 2017;12(1):50-59. 13. Fremeaux-Bacchi V, et al. *Clin J Am Soc Nephrol.* 2013;8(4):554-562. 14. Bruel A, et al. *Clin J Am Soc Nephrol.* 2017;12(8):1237-1247. 15. Fakhouri F, et al. *J Am Soc Nephrol.* 2010;21(5):859-867. 16. Huerta A, et al. *Kidney Int.* 2018;93:450-459. 17. Noris M, Remuzzi G. *New Engl J Med.* 2009;361(17):1676-1687.

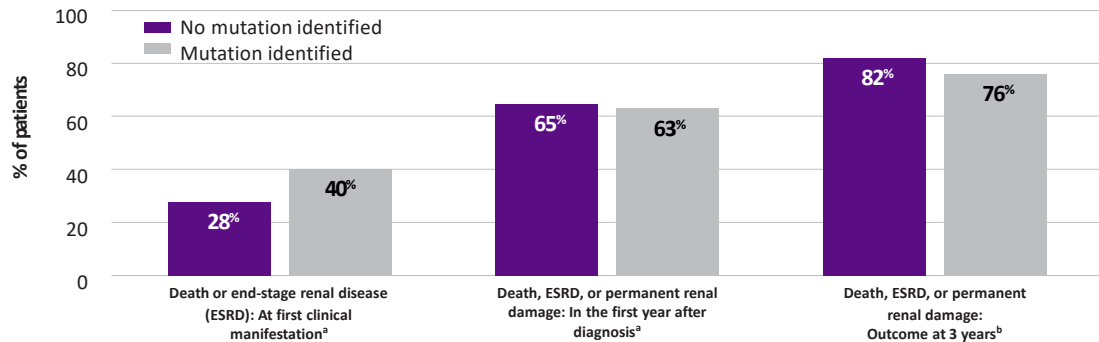
US/UNB-a/0113 20

Examples of factors that may increase risk for TMA manifestations in patients with atypical-HUS are shown on this slide, and include renal transplant, patient age, identified genetic mutation, postpartum, and history of TMA.

This is not a comprehensive list, but is intended to provide examples of factors that may increase risk for TMA. Anything that amplifies complement is a risk factor for TMA.

The number of new genetic abnormalities discovered in patients with atypical-HUS continues to increase over time¹⁻⁴

High morbidity and mortality regardless of mutation identification^{1,5}



Identification of genetic complement mutations is not required for atypical-HUS diagnosis or management decisions⁶

ESRD=end-stage renal disease; HUS=hemolytic uremic syndrome.

^aMutations consisted of membrane cofactor protein (MCP), complement factor H (CFH), and factor I (CFI). No mutation identified: n=81. Mutation identified: n=60.

^bMutations consisted of MCP, CFH, CFI, complement component 3 (C3), and thrombomodulin (THBD). No mutation identified: n=119. Mutation identified: n=116.

1. Noris M, et al. *Clin J Am Soc Nephrol*. 2010;5(10):1844-1859. 2. Bu F, et al. *J Am Soc Nephrol*. 2014;25(1):55-64. 3. George JN, et al. *N Engl J Med*. 2014;371:654-666. 4. Structural Immunology Group. Database of complement gene variants. Accessed November 15, 2018. http://www.complement-db.org/advance_search_result.s.php?dosearch=1&source=lab&dosearch=1&source=lab&genead%5B%5D=all&reference=&condition%5B%5D=aHUS&cutoff=0.01 5. Caprioli J, et al. *Blood*. 2006;108(4):1267-1279. 6. Azoulay E, et al. *Chest*. 2017;152(2):424-434.

US/UNB-a/0113 21

Identification of genetic complement mutations is not required for atypical-HUS diagnosis or management decisions.

REFERENCE

1. Azoulay E, et al. *Chest*. 2017;152(2):424-434.

Summary

- Atypical-HUS is characterized by thrombotic microangiopathy that can involve multiple organ systems¹
- Atypical-HUS is a complement-mediated disease, which can be unmasked by complement-amplifying conditions such as malignant hypertension and pregnancy/postpartum complications^{1,2}
- Atypical-HUS is a life-threatening disease
 - Promptly differentiate from TTP and STEC-HUS using ADAMTS13 activity and Shiga toxin testing and initiate appropriate management plan early for atypical-HUS^{1,3}

ADAMTS13=a disintegrin and metalloproteinase with a thrombospondin type 1 motif member 13; HUS=hemolytic uremic syndrome; STEC-HUS=Shiga toxin-producing *Escherichia coli* hemolytic uremic syndrome; TTP=thrombotic thrombocytopenic purpura.

1. Laurence J, et al. *Clin Adv Hematol Oncol*. 2016;14(11):2-15. 2. Legendre CM, et al. *N Engl J Med*. 2013;368(23):2169-2181. 3. Li A, et al. *Transfusion*. 2016;56:2069-2077.

US/UNB-a/0113 22



This promotional program is sponsored by Alexion Pharmaceuticals, Inc.
© 2021, Alexion Pharmaceuticals, Inc. All rights reserved.

US/UNB-a/0113 23